



PATIENT

Agnes Muntz

PRESENTING CLINICAL SIGNS

History: Recheck echo.
-Pertinent previous findings (6/22 MML): Mild MR, no LA or LVE. LA: 2.6, LV: 3.8.

SPECIES

Canine

ELECTROCARDIOGRAPHIC FINDINGS

A six lead ECG is available at 25mm/s; 10mm/mV. The average heart rate is 110bpm (range 75-150bpm). The rhythm is sinus in origin, with a p for every QRS complex and vice versa. The P wave morphology is positive with a normal dimension. Normal PR. The QRS morphology is positive with normal dimension. MEA is normal. No ectopic beats, pauses or dysrhythmias observed.

BREED

Basset Hound

ECG diagnosis: Normal sinus rhythm with profound respiratory variation.

SEX

Female Spayed

ECHOCARDIOGRAM FINDINGS

2D, m-mode, color flow and doppler imaging is available. Mild diffuse thickening of mitral valve leaflets with no prolapse into the left atrial lumen. Mild eccentric mitral regurgitation with no left atrial dilation. Normal LV diameter with adequate myocardial function. The tricuspid valve appears normal with no tricuspid regurgitation. Normal right atrial and ventricular diameter and morphology indicating no overt evidence of pulmonary arterial hypertension. The pulmonic and aortic valves are normal in morphology and mobility. Normal pulmonic and aortic outflow velocities with laminar flow. No aortic or pulmonic insufficiency. No pericardial or pleural effusion noted. No obvious cardiac masses.

AGE

8 years

WEIGHT

≈50lbs

CARDIAC CHART

INTERPRETED BY

Maggie Machen Lamy,
DVM, DACVIM
(Cardiology)

CANINE CARDIAC PARAMETERS	MR VMAX (m/s)	TR VMAX (m/s)	LA/AO (Boon method)	LA/AO (Heart Base; Swe)	FS (%)	EF (%)	EPSS (cm)
NORMAL PARAMETER	4.5-5.5	<2.7	1.3	<1.6	28-40	40-100	<0.6
PATIENT	NM	NA	NM	1.2	51	83	NM
CANINE CARDIAC PARAMETERS	HR (BPM)	AV VMAX (m/s)	PV MAX (m/s)	BODY WEIGHT (kg)	LA 2D short axis Base view (cm)	LVIDd Avg; 2D and m-mode short axis (cm)	LVIDs Avg; 2D and m-mode short axis (cm)
NORMAL PARAMETER	50-100	0.7-1.7	0.7-1.6	BELOW	BELOW	BELOW	BELOW
PATIENT	NM	0.8	0.8	≈22.7	2.5	3.7	1.8
*Normal chamber parameters expressed as a mean value (SD)				3	1.27 (5.3)	2.46 (2.46)	1.36 (5.5)
BODY WEIGHT DEPENDENT PARAMETERS				5	1.40 (4.5)	2.74 (5.2)	1.60 (4.7)
*Note: All measurements based upon multi-modal images and methods. An average value is reported.				10	1.50 (3.8)	3.27 (3.5)	2.06 (3.1)
				15	1.83 (2.0)	3.71 (2.4)	2.43 (2.1)
				20	2.02 (1.9)	4.14 (2.2)	2.80 (2.0)
				25	2.18 (2.4)	4.48 (2.9)	3.10 (2.5)
				30	2.33 (3.3)	4.83 (3.9)	3.39 (3.4)
				35	2.48 (4.3)	5.17 (5.0)	3.69 (4.5)
				40	2.62 (5.2)	5.48 (6.1)	3.96 (5.4)
				50	2.88 (7.1)	6.07 (8.3)	4.46 (7.4)

Adapted from June Boon, Veterinary Echocardiography, 1998
Rishniw M and Hollis NE, J Vet Intern Med 2000; 14:429-435
Hansson et al, Vet Rad and Ultrasound 2002
Bonagura et al. Echocardiography: principles of interpretation, Vet Clin North Am 15:1177, 1995

IMAGING PERFORMED BY

Dana Alterman,
RDMS, LVT

HOSPITAL NAME

Eubank Animal Clinic

REFERRING VET

Dr. Russman

INVOICE

31988

DATE

7/28/23

INTERPRETATION OF THE FINDINGS & FURTHER RECOMMENDATIONS

Chronic degenerative valve disease persists with overall stability. Mild mitral regurgitation is unchanged without left or right heart enlargement. No additional issues have developed. The



PATIENT

Agnes Muntz

ECG is unremarkable with a profound respiratory sinus arrhythmia. This likely reflects high vagal tone.

SPECIES

Canine

Given these findings, no cardiac medications are indicated. Assessment of progression in the future will help predict long term prognosis, which is highly variable at this stage. Omega fatty acid supplementation and mild salt restriction may be of some long-term benefit. Monitor for development of a cough, labored breathing, exercise intolerance or collapse episodes.

BREED

Basset Hound

Anesthetic risk is considered mild if needed. Premedicate with a vagolytic. Cardiac protective drug choices (opioid/benzodiazepine premedication, propofol or alfaxalone induction, isoflurane gas) are recommended. Pre-oxygenate for 5-10 minutes prior to induction. Monitor for arrhythmias, hypotension, and hypoxia both intra and post-operatively and intervene as necessary. Mild IV fluid restriction is recommended to avoid fluid overload.

SEX

Female Spayed

Recommend conservative monitoring with a recheck echocardiogram annually, sooner if clinical signs arise.

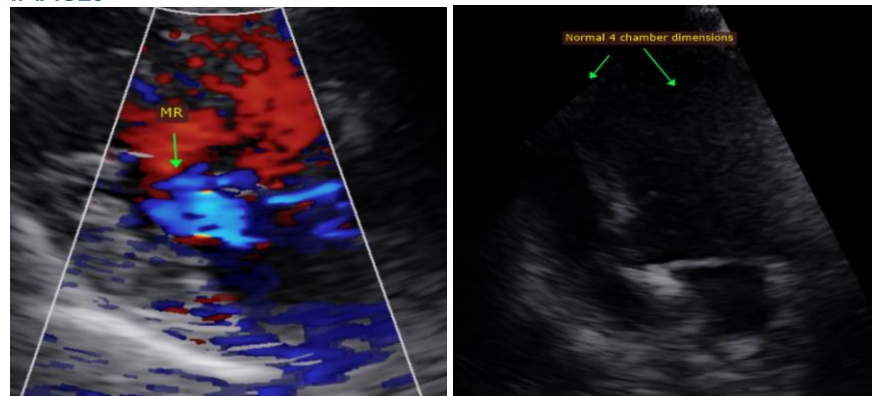
AGE

8 years

IMAGES

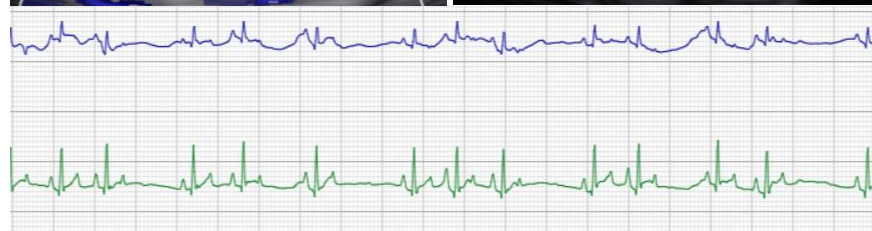WEIGHT

≈50lbs



INTERPRETED BY

Maggie Machen Lamy,
DVM, DACVIM
(Cardiology)



IMAGING PERFORMED BY

Dana Alterman,
RDCS, LVT

HOSPITAL NAME

Eubank Animal Clinic

REFERRING VET

Dr. Russman

The information and recommendations provided are based on the images presented by the referring veterinarian. No evaluation can be communicated regarding pathology that was not visible in the image/video clips provided.

INVOICE

31988

Thank you for this referral. This report was generated using transcription software, and minor dictation errors may be present. If the clinical or image interpretation does not parallel your findings or if I can be of any further assistance, please contact me.

DATE

7/28/23

Maggie Machen Lamy, DVM
Diplomate of the American College of Veterinary Internal Medicine (Cardiology)
info@sonopath.com